



e-ISSN: 2319-8753 | p-ISSN: 2347-6710

IJRSET

International Journal of Innovative Research in
SCIENCE | ENGINEERING | TECHNOLOGY

INTERNATIONAL JOURNAL OF INNOVATIVE RESEARCH

IN SCIENCE | ENGINEERING | TECHNOLOGY

Volume 10, Issue 11, November 2021

ISSN INTERNATIONAL
STANDARD
SERIAL
NUMBER
INDIA

Impact Factor: 7.569

 9940 572 462

 6381 907 438

 ijrset@gmail.com

 www.ijrset.com



An Auxiliary Classification and Diagnosis of Lung Cancer Subtypes Based on Histopathological Images

Dr. R. Poovendran¹, V. Santhosh², Y. Gokul³, J. Hariprasanth⁴

Professor, Dept. of Electronics and Communications Engineering, Adhiyamaan College of Engineering, Hosur,
Tamil Nadu, India ¹

U. G Scholars, Dept. of Electronics and Communications Engineering, Adhiyamaan College of Engineering, Hosur,
Tamil Nadu, India ²⁻⁴

ABSTRACT: Lung cancer (LC) is one among the foremost serious cancers of human health. Histopathology reports on surgical cancer specimens have gotten a lot of and a lot of advanced. For this drawback of incomplete experimental subjects within the computer-aided diagnosing of carcinoma subtypes, technique} enclosed comparatively rare respiratory organ adenosquamous cancer (ASC) samples for the primary time and projected a computer-aided diagnosing method supported histopathological pictures of ASC, respiratory organ epithelial cell cancer (LUSC) and tiny cell respiratory organ cancer (SCLC). The support vector machines (SVM) classifier was accustomed classify LC subtypes, and also the receiver operational graphical record and space beneath the curve, were accustomed build it a lot of intuitive judge the generalization ability of the classifier. Finally, through a horizontal comparison with a spread of thought classification models, experiments show that the classification impact achieved by the SVM model is that the best.

KEYWORDS: Lungcancer, classification, pathology, immunohistochemistry, molecular testing

I. INTRODUCTION

According to the 2018 International Agency for analysis on Cancer statistics, there'll be two.1 million new cases of LC and one.8 million deaths worldwide. because of its high morbidity and mortality, it's become one amongst the foremost serious cancers threatening human health Visual analysis by nurses of histopathological LC pictures is one amongst the foremost necessary ways in which to diagnose LC subtypes. However, it's sophisticated and difficult for pathologists to review thousands of histopathological pictures, and it's terribly tough for physicians with very little expertise. Therefore, to alleviate the pressure on doctors and improve the accuracy and potency of identification, it's notably necessary to review the computer-aided identification model of LC. From the attitude of pathology and treatment, LC will be divided into non-small cell respiratory organ malignant neoplastic disease (NSCLC) and tiny cell respiratory organ malignant neoplastic disease (SCLC), of that 80%-85% are NSCLC and also the rest are SCLC. the most histologic forms of NSCLC are respiratory organ {adenocarcinoma glandular cancer|glandular malignant neoplastic disease|carcinoma} (ADC) and respiratory organ epithelial cell carcinoma (LUSC). the opposite histologic forms of NSCLC are respiratory organ adenosquamous malignant neoplastic disease (ASC), large-cell malignant neoplastic disease. particularly, ASC may be a comparatively rare subtype of NSCLC that accounts for zero.3-5% of all NSCLCs. as a result of the various histopathological forms of LC, the treatments received also are totally different. once determinant the division of respiratory organ tissue, acceptable treatment modalities is also elect, like acceptable surgical surgical process, therapy, actinotherapy, targeted cell medical aid, and physiatrics. additionally, LC diagnostic errors will be avoided, multiple clinical operational pressures will be reduced, patient survival time will be accrued and quality of patient health improved. The LC imaging examination ways primarily include: (1) X-ray photography, that's one among the foremost basic internal organ imaging examination ways in which, but the resolution of the photography is low and there ar blind spots at intervals the examination.



II. OBJECTIVES

This project was to apply the SVM algorithm to the classification of LC histopathological images, which demonstrates the tremendous potential of ML algorithms to be used in the diagnosis of LC subtypes.

III. LITERATURE SURVEY

1. Yu, K.-H., Zhang, C., Berry, G. J., Altman, R. B., R, C., Rubin, D. L., and Snyder, M “Predicting non-small cell carcinoma prognosis by absolutely automatic microscopic pathology image. A list of standardized options has been extracted from the tissue regions and therefore the use of many recent mechanical instrumentality for every WSI is employed. whereas handstitched ways work well, there's a growing trend towards deeper learning pathways, wherever networks square measure able to learn solid representations. As a results of this sturdy feature illustration, the most recent 3-6 deep networks have gained vital accuracy in massive image recognition functions.7 several WSI classification ways use a location-based approach thanks to laptop complexness in process multi-gig pel pictures.

2. Coudray, N., Moreira, A. L., Sakellaropoulos, T., Fenyo, D., Razavian, N., and Tsirigos, A “Classification and mutation prediction from non-small cell carcinoma histopathology pictures exploitation deep learning,” Separated NSCLC WSIs use in-depth patch-by-patch study, however conjointly predict genetically changed genes. in step with the carcinoma class, the authors used the v3 network style to differentiate the insertion spots into LUAD, LUSC and commonplace. The authors assumed that {each one that everyone} the layers among each WSI had an equivalent label and so failed to distinguish between diagnostic and non-diagnostic regions. This approach may lead to an oversized range of surprises in non-diagnostic and coaching districts that may take a protracted time to come back along.

3. Sagamihara, P., & Govindarajan, S. Lungs neoplasm detection and classifications exploitation K-Mean agglomeration, PB Sangamithraa and Govindaraju, within the model projected at the first, CT pictures square measure processed to get rid of noise, within the next section the fuzzy k-means algorithmare is employed to differentiate the tumour within the lungs, then alternative classification results square measure increased exploitation K-means to maneuver nearer to succeeding step. of the lungs square measure extracted from CT pictures like entropy, correlation, homogeneity, SSIM and PSNR, the component domain used mathematical ways referred to as the grey scale co-occurrence matrix (GLCM) and within the final section Classification was performed employing a NN supervised neural network like Back Propagation BPNN to diagnose cancerous lungs. This model achieved ninety.7% accuracy, however the accuracy will be improved by making a programming writing method like Support Vector Machine.

4. Jin, Zhang, Y., & Jin. pulmonic Nodules Detections supported CT Image exploitation Convolutional Neural Networks, ninth International conference on procedure Intelligence and style, Jin, X., Zhang, Y., & Jin, Q., to seek out the carcinoma projected model employed by C Neural Networks (convolution NN) as a way of differentiation within the laptop power-assisted Diagnostic (CAD) system. And this model has achieved Associate in Nursingd achieved an accuracy of eighty-four.6%, sensitivity of eighty-two.5% and specificity of eighty-six.7%. nonetheless accuracy isn't enough; the advantage of the projected system is that it uses a circular filter within the targeted regions whereas extracting that helps to scale back the overall price of the acquisition and coaching section.

5. Zakariya Suleman Zubi and Rema Saad. Improves the Program of Lungs Cancers exploitation data processing Technique, Journal of computer code Engineering and Applications, Zakaria Suliman Zubi and al., Have prompt variety of knowledge mining ways. The carcinoma patient's information contains medical pictures X-ray of the higher organic structure that is split into 3 combined categories; that square measure unhealthy, common and dangerous. Healthy patients don't seem to be tumors isolated from traditional patients; respiratory organ nodules will be a dangerous initial stage or common lung while not cancer, and therefore the most dangerous square measure cancer patients. The CAD system operates during a style of stages, pattern recognition is that the formulation of the extraction method and therefore the separation method. The projected system has used X-ray imaging films that square measure less correct compared to CT imaging, and analysis suggests that future work can transcend the employment of CT imaging to get a better designation of Cancer respiratory organ. adoption.

IV. EXISTING METHOD

LC imaging imaging methods mainly include: X-ray photography, which is one of the most basic methods of lung testing, but image imaging is low and there are invisible areas on the test. Computed tomography (CT), in particular,



chest CT has benefits in locating the first peripheral LC and identifying the location of the lesion. Currently, it is one of the most widely used diagnostic methods for diagnosis and stage LC. However, one of the limitations of using CT scans is that in patients who are routinely tested, it is necessary to consider the effect of radiation exposure produced by this activity.

V. PROPOSED METHOD

The proposed program includes ASC (lung adenosquamous carcinoma) sample data for the first time and introduces a computer-assisted model for the automatic detection of LC subtypes based on histopathological images of LC (lung cancer). First, texture analysis methods are used to extract the-size features of histopathological LC images, and the relevant features (Relief) algorithm are used to select the feature. Compared to a variety of machine learning (ML) models, the SVM model achieves better LC subtype segmentation. The main contributions of this program are the first to incorporate rare ASCs into images of lung organs and to use them in the automatic classification of LC subtypes. This program was the first to use the SVM algorithm in the classification of LC histopathological images, indicating the great potential of ML algorithms to be used in evaluating LC subtypes

VI. METHODOLOGY

The input image is histopathological image of lung cancer subtype is given the software, first image will be preprocessed for separating structure and remove the noise using gaussian filtering. The adaptive histogram equalization is used for improve on this by transforming each pixel with a transformation function derived from a neighborhood region. In its simplest form, each pixel is transformed based on the histogram of a square surrounding the pixel, Histogram Equalization. Histogram equalization is a technique for adjusting image intensities to enhance contrast. Feature extraction is a process of dimensionality reduction by which an initial set of raw data is reduced to more manageable groups for processing.

VII. BLOCK DIAGRAM

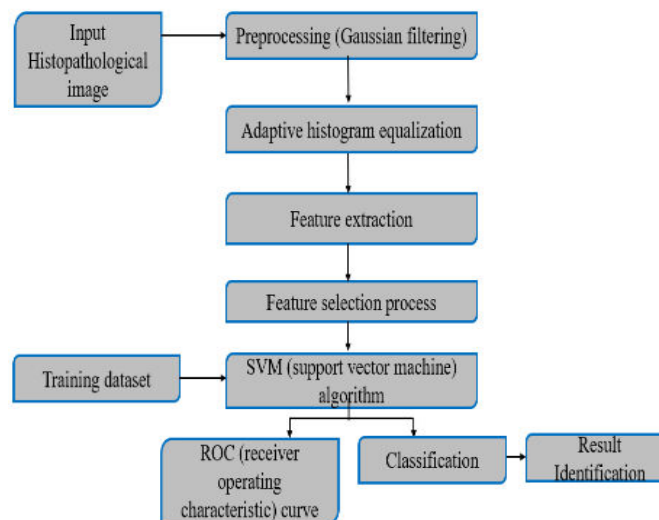



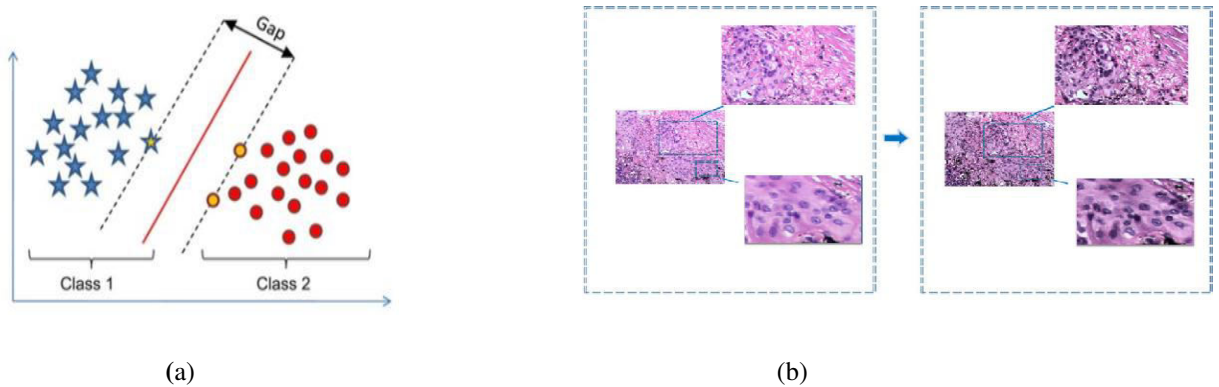
Figure 1: block diagram

VIII. SUPPORT VECTOR MACHINE ALGORITHM

Support Vector Machine or SVM is one among the foremost widespread supervised Learning algorithms, that is employed for Classification further as Regression issues. However, primarily, it's used for Classification issues in Machine Learning.

The goal of the SVM formula is to make the most effective line or call boundary that may segregate n-dimensional area into categories in order that we are able to simply place the new datum within the correct class within the future. This best call boundary is termed a hyperplane.

SVM chooses the intense points/vectors that facilitate in making the hyperplane. These extreme cases are referred to as support vectors, and thence formula is termed as Support Vector Machine.



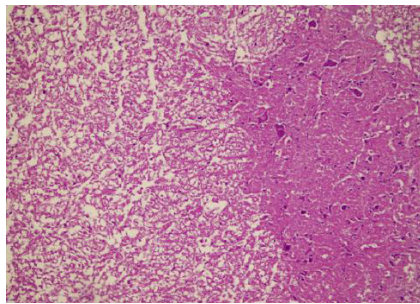
(c)

Figure 2 (a) support vector machine algorithm (b) The classification of LC histopathological images using SVM algorithm (c) Gray coded restored image

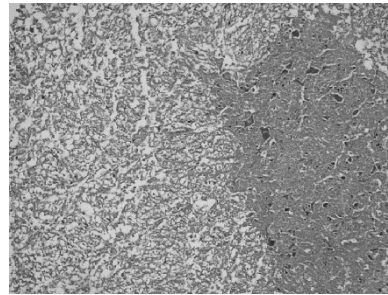
The Gray values distribution of the R D a pair of and N D sixteen schemes was comparatively uniform. However, the experiments showed that the extracted 59-dimensional options were a lot of useful in characteristic histopathological pictures of LC once R D a pair of and N D eight, whereas the extracted options had a lot of redundant data once R D a pair of and N D sixteen, that wasn't causative to the development of the next classification effect

IX. RESULT AND DICUSSION


Thus, this detection of lung cancer subtype classification using image processing techniques is implemented successfully. The expected output result image is shown below



(a)



(b)



(c)

```
total classes images 12
['img0', 'img1', 'img10', 'img2', 'img3', 'img4', 'img5', 'img6', 'img7', 'img8', 'img9', 'Thumbs']
12
4
image loading.....
pre-process start....
segment start.....
predicted output
svm processing....
squamous cell carcinoma ratio P=0.062 for univariate analysis
lung infected cancer
```

(d)

Figure 3: Lung Cancer Detection (a) Original image (b) Gray level image, (c) Canny image, (d) Carcinoma ratio

X. CONCLUSION

This project would incorporate the SVM algorithm into the classification of histopathological LC images. We have included histopathological images of LUSC, ASC and SCLC. Experimental results show that SVM has excellent differentiation of the subtypes of lung cancer subtypes, providing a good guideline for the separation of lung images. It also provides an accurate guide to the division of medical images into complex tissue.

REFERENCES

- [1] W. Cao, R. Wu, G. Cao, and Z. He, "A comprehensive review of computer-aided designation of pneumonic nodules supported X-radiation scans," *IEEE Access*, vol. 8, pp. 154007–154023, 2020.
- [2] N. Nasrullah, J. Sang, M. S. Alam, M. Mateen, B. Cai, and H. Hu, "Automated respiratory organ nodule detection and classification victimization deep learning combined with multiple methods," *Sensors*, vol. 19, no. 17, p. 3722, Aug. 2019.
- [3] X. Zhao, S. Qi, B. Zhang, H. Ma, W. Qian, Y. Yao, and J. Sun, "Deep CNN models for pneumonic nodule classification: Model modification, model integration, and transfer learning," *J. X-Ray Sci. Technol.*, vol. 27, no. 4, pp. 615–629, Sep. 2019.
- [4] M. Kriegsmann, C. Haag, C. A. Weis, G. Steinbuss, and K. Kriegsmann, "Deep learning for the classification of small-cell and non-small-cell carcinoma," *Cancers*, vol. 12, no. 6, p. 1604, 2020.
- [5] P. Ocampo, A. Moreira, N. Coudray, T. Sakellaropoulos, N. Narula, M. Snuderl, D. Fenyo, N. Razavian, and A. Tsigos, "Classification and mutation prediction from non-small cell carcinoma histopathology pictures victimization deep learning," *J. pectoral Oncol.*, vol. 13, no. 10, p. S562, Oct. 2018.
- [6] X. Liu, C. Wang, J. Bai, and G. Liao, "Fine-tuning pre-trained convolutional neural networks for viscus malignant tumor sickness classification on magnification narrow-band imaging pictures," *Neurocomputing*, vol. 392, pp. 253–267, Jun. 2020.
- [7] F. Kanavati, G. Toyokawa, S. Momosaki, M. Rambeau, Y. Kozuma, F. Shoji, K. Yamazaki, S. Takeo, O. Iizuka, and M. Tsuneki, "Weakly supervised learning for lung carcinoma classification using deep learning," *Sci. Rep.*, vol. 10, no. 1, pp. 1–11, Jun. 2020.



- [8] Y. Han, Y. Ma, Z. Wu, F. Zhang, D. Zheng, X. Liu, L. Tao, Z. Liang, Z. Yang, X. Li, J. Huang, and X. Guo, "Histologic subtype classification of non-small cell lung cancer using PET/CT images," *Eur. J. Nucl. Med. Mol. Imag.*, vol. 48, no. 2, pp. 350–360, Feb. 2021.
- [9] S. Lian, Y. Huang, H. Yang, and H. Zhao, "Serum carbohydrate antigen 12-5 level enhances the prognostic value in primary adenosquamous carcinoma of the lung: A two-institutional experience," *Interact. Cardio Vascular Thoracic Surg.*, vol. 22, no. 4, pp. 419–424, Apr. 2017.
- [10] H. Maeda, A. Matsumura, T. Kawabata, T. Suito, O. Kawashima, T. Watanabe, K. Okabayashi, and I. Kubota, "Adenosquamous carcinoma of the lung: Surgical results as compared with squamous cell and adenocarcinoma cases," *Eur. J. Cardio-Thoracic Surg.*, vol. 41, no. 2, pp. 357–361, Feb. 2018.

BIOGRAPHY



Dr. R. Poovendran,
Associate Professor,
Electronics and Communication Engineering
Department,
Adhiyamaan College of Engineering,
Anna University.



V. Santhosh,
Student,
Electronics and Communication Engineering
Department,
Adhiyamaan College of Engineering,
Anna University.



Y. Gokul,
Student,
Electronics and Communication Engineering
Department,
Adhiyamaan College of Engineering,
Anna University.



J. Hariprasanth,
Student,
Electronics and Communication Engineering
Department,
Adhiyamaan College of Engineering,
Anna University.



Impact Factor:
7.569



INTERNATIONAL JOURNAL OF INNOVATIVE RESEARCH

IN SCIENCE | ENGINEERING | TECHNOLOGY

 9940 572 462  6381 907 438  ijirset@gmail.com



www.ijirset.com

Scan to save the contact details